



PRESENTING CLINICAL SIGNS

History: Grade III/VI murmur. Asymptomatic. Pre-anesthetic evaluation (dental).

DATE

11/3/22

ECHOCARDIOGRAPHIC FINDINGS

2D, M-mode, and Doppler study.

PERFORMED BY:

Shari Reffi, CVT

Left atrial size is normal. The mitral valve is normal. Left ventricular wall thickness is normal. Left ventricular internal dimensions are normal. Left ventricular systolic function is normal. The aorta and aortic valve are normal. Right atrial and right ventricular dimensions are normal. The tricuspid valve is normal. The pulmonary artery and pulmonic valve are normal. No shunting lesions are visualized. No pericardial effusion or cardiac masses are seen.

INTERPRETED BY

Keith Blass, DVM,
MS, DACVIM
(Cardiology)

LA/Ao - 1.15
IVSd - 5.0 mm
LVPWd - 4.8 mm
LVIDd - 14.0 mm
LVIDs - 6.8 mm
FS - 51.4%
LVOT - 0.93 m/s
RVOT - 0.75 m/s

PATIENT

Buddy Zey

ASSESSMENT/RECOMMENDATIONS

Normal echocardiogram

SPECIES

Feline

This examination demonstrates no evidence of structural heart disease. While a definitive reason for Buddy's murmur was not identified, it's likely that his murmur is functional/innocent in nature, as no flow abnormalities that could result in the development of a pathologic murmur were appreciated in the image set.

BREED

DSH

Buddy's cardiovascular risk for general anesthesia is low based on this exam, and there are no contraindications to the use of any specific anesthetic agents.

No therapy is recommended based on this exam.

SEX

MN

A recheck echocardiogram is recommended if the characteristics of Buddy's murmur change, or if other new physical exam and/or clinical abnormalities suggestive of cardiac dysfunction develop.

AGE

9 y

WEIGHT

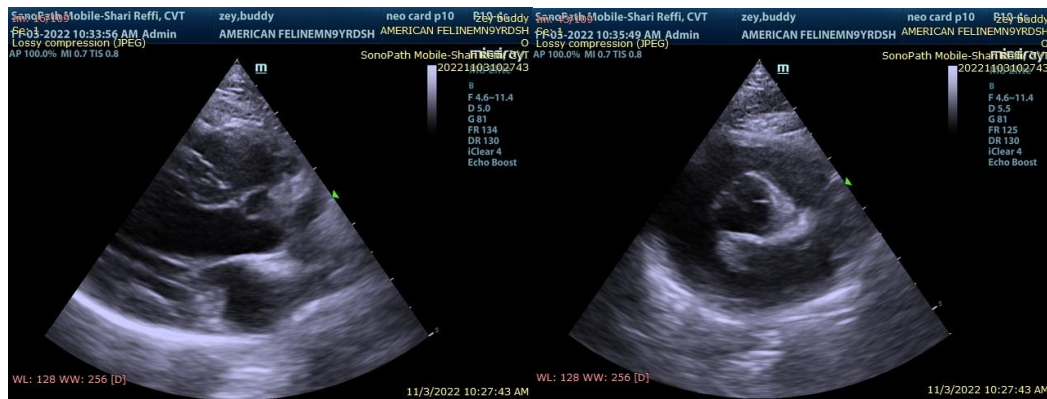
10.56 lb

HOSPITAL NAME

American AH

REFERRING VET

Dr. Stockmal



The information and recommendations provided are based on the images presented by the referring veterinarian. No evaluation can be communicated regarding pathology that was not



visible in the image/video clips provided.

DATE Thank you for this referral. If the clinical or image interpretation does not parallel your findings or if I can be of any further assistance please contact me.

11/3/22

PERFORMED BY: Keith Blass, DVM, MS, DACVIM (Cardiology)
KeithBlass@gmail.com
631-804-5754

Shari Reffi, CVT

INTERPRETED BY

Keith Blass, DVM,
MS, DACVIM
(Cardiology)

PATIENT

Buddy Zey

SPECIES

Feline

BREED

DSH

SEX

MN

AGE

9 y

WEIGHT

10.56 lb

HOSPITAL NAME

American AH

REFERRING VET

Dr. Stockmal